



CHOLANGIOCELLULAR CARCINOMA IN A DUCK – A CASE REPORT

Received: 21.03.2019

Accepted: 25.04.2019

Cholangiocellular carcinomas are malignant tumors of biliary epithelium which usually arise from intrahepatic and extra hepatic bile ducts. These neoplasms occur frequently in ducks. Single or multiple nodules may be present within the liver, which are typically firm, raised, often with central depression (umbilicated), pale gray to tan colored. The tumors are composed of cells that resemble biliary epithelium. Characteristically well differentiated carcinomas are organized into tubular or acinar arrangement. In case of less differentiated neoplasms, some acinar arrangements can be detected among solid masses of neoplastic cells. Poorly differentiated carcinomas are composed of packets or cords of cells with areas of squamous differentiation. The epithelial components of neoplasms are usually separated by fibrous connective tissue. The amount of connective tissue varies among tumors but an abundant deposition of collagen termed as scirrhous response is relatively common and is responsible for the firm texture of these neoplasms. Multiple sites of local invasion by tumor cells to the surrounding hepatic parenchyma are usually seen. Multifocal hepatic necrosis are also common in the adjacent parenchyma. Metastasis to extra hepatic sites is common, particularly to the adjacent lymph nodes of the cranial abdomen, lungs, or by seeding into abdominal cavity. Peritoneal carcinomatosis can produce variably sized nodules within the mesentery and on the serosal surface of the viscera.

Carcass of a 1 year old female white pekin duck weighing around 3.5-4 kg from University Poultry and Duck Farm, Mannuthy was submitted to the Department of

Veterinary Pathology, College of Veterinary and Animal Sciences, Mannuthy for post-mortem examination. On detailed gross examination revealed multi focal, yellowish, fluid filled umbilicated nodules of 3-4 cm diameter were seen embedded in the liver parenchyma and few of the nodules were cystic containing bile stained watery fluid. For cytological examination, impression smears were taken and stained by routine Leishman-Giemsa staining method. Representative tissues from the lesions were collected for histopathological investigations. The tissue samples were fixed in 10 per cent neutral buffered formalin. Post fixation, the tissues were processed by routine paraffin embedding technique and 4-5 μ m thick sections were stained by hematoxylin and eosin (H&E) for histopathological examination.

Gross examination revealed multi focal yellowish, fluid filled umbilicated nodules of 3-4 cm diameter embedded in the liver parenchyma and few of the nodules were cystic containing bile stained watery fluid. Impression smear from liver revealed cells showing anisocytosis, anisokaryosis, vacuolation and hyperchromasia. Histopathologically, nodules were characterized by bile duct proliferation with fibrous tissue encapsulation and varying sized bile ducts lined by multilayered anaplastic epithelium with variable size and staining intensity, congestion of hepatic sinusoids and disruption in the arrangement of hepatic cords. The main causes of hepatic tumors are mycotoxins (especially aflatoxins), chemical carcinogens and certain virus infections such as Duck Hepatitis B virus (Carnaghan, 1965; Rigdon, 1972; Chu *et al.*, 1980; Malkinson, 1982 and Chang *et al.*, 1983). Chambal Konch

(2007) conducted studies on the incidence and pathology of duck disease in Assam Agricultural University from August 2003 to June 2005. He reported that aflatoxicosis accounted for about 40.1% mortality among 1723 ducks. Chu *et al.* (1980) successfully induced hepatic tumors in ducks with aflatoxin B. After investigating the epidemiology and etiology of hepatic carcinomas in a duck farm, Chang *et al.* (1983) suggested that apart from mycotoxins, certain trace elements, such as copper, zinc, molybdenum and iron, and the concentration of nitrite in the water might play an important role in causing hepatic tumors in ducks. Goyal *et al.* (2005) observed proliferation of biliary epithelial cells in cholangiocellular carcinomas which could be probably due to increased metabolic activity in the newly proliferating cells. The present case was identified as cholangiocellular carcinoma from the gross, cytological and histopathological findings. The incidence of cholangiocellular carcinoma can be reduced by regular testing of aflatoxin levels in feed, vaccination against viral infections like duck hepatitis B virus, and proper husbandry conditions.

ACKNOWLEDGEMENTS

The authors would like to acknowledge the staff members and colleagues of Department of Veterinary Pathology, College of Veterinary and Animal Sciences, Mannuthy for their valuable support.

References

- Bancroft, J.D and Gamble, M. 2008. Theory and Practice of Histological Techniques. 6th edn., Churchill Livingstone, United States of America. 725.
- Beasley, P. R. and Hwang, L.V. 1984. Hepatocellular carcinoma and hepatitis B virus. *Semin. Liver Dis.*, 4: 113-121.
- Campbell, J. G. 1949. Spontaneous hepatocellular and cholangiocellular carcinoma in the duck- an experimental study. *Poult. Res. Gen. Edinburgh*, pp. 198-210.
- Carnaghan, R.B.A. 1965. Hepatic tumours in ducks fed a low level of toxic groundnut meal. *Nature*, 208 - 308.

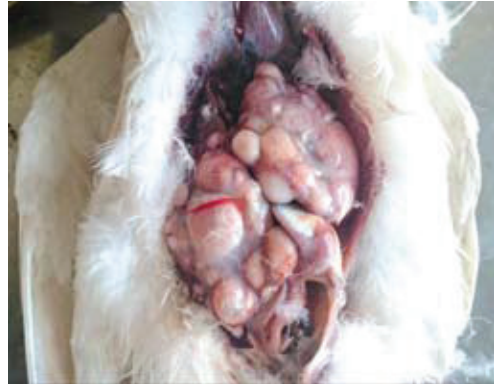

Fig 1: Liver containing varying sized nodules

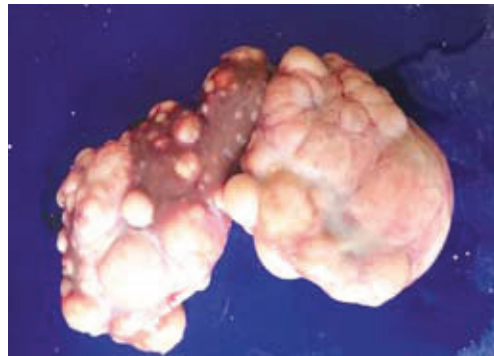

Fig 2: Multi focal yellowish, fluid filled umbilicated nodules of 3-4 cm diameter embedded in the liver parenchyma with a few cystic nodules.

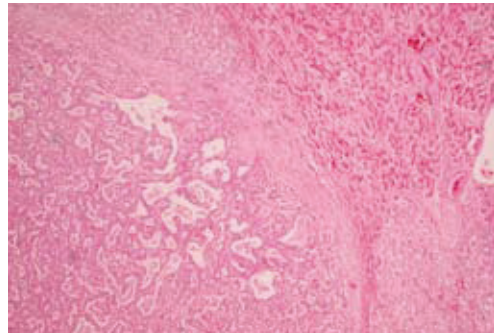


Fig 3: Bile duct proliferation with fibrous tissue encapsulation and congestion of hepatic sinusoids

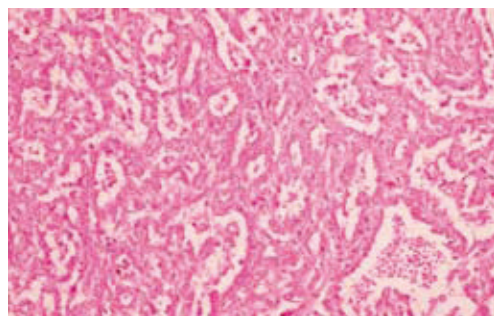


Fig 4: Variable sized bile ducts lined by multilayered anaplastic epithelium.

- Chambal, K. 2007. Studies on the incidence and pathology of duck disease in Assam Agricultural University . *M.V.Sc thesis, Indian J. Vet. Pathol.*, **31(2)**: 185.
- Chang, G., Chan, Y. & Lau, C. 1983. Neoplasms in a flock of white Peking Duck. *Acta Veterinaria et Zootechnica Sinica*, **14**, 137-14.
- Chu, K.H., Lin, Z.Y., Chou, Y.S. & Zin, A.S. 1980. The experimental primary liver cancer of ducks. *Acta Veterinaria et Zootechnica Sinica*, **11**, 109-118
- Cova, L., Wild, C.P., Mehrotra, R., Turusov, V., Shirai, T., Lambert, R., Jacquet, C., Tomatis, L., Trepo, C., and Montesano, R. 1990. Contribution of Aflatoxin B1 and Hepatitis B Virus Infection in the Induction of Liver Tumors in Ducks. *Can. Res.* **50**: 2156-2163.
- Devi, V. R., Sreelatha, C. and Ahmed, M. N. (1999). Cholangiocellular carcinoma in ducks- A report. *Indian Vet. J.*, **76**: 1126-27.
- Goswami, S., Mukit, A. and Bhatiacharyn. 1998. Histochemical study on chronic atlatoxicosis in ducks. *Ind. J. Anim. Sci.* **68 (11)**: 1181-1182.
- Goyal, D., Singh, A., Sood, N., Gupta, K. and Sood, N.K. 2005. A rare case of cholangiohepatocellular carcinoma in Poultry. *Ind. J. Vet. Pathol.* **29(1)**: 52-53.
- Ling, Y.S., Guo, Y.J. and Yang, L.K. 2007. Pathological observations of hepatic tumours in ducks. *Avian Pathology*, **22:1**, 131-140.
- Luna, L.G. 1968. Manual of Histologic Staining Methods of the Armed Forces Institute of Pathology. 3rd edn., McGraw Hill Book Company, New York. 207.
- Malkinson, M. 1982. Tumor-producing disease reported from ducks. *Proceedings, Western Poultry Disease Conference*.
- Moulton, J.E. Tumors of the pancreas, liver, gall bladder, and mesothelium. In: *Tumors in domestic animals*. J. E. Moulton, ed. University of California Press, Berkeley. pp. 279-280. 1978.
- Potter, K., Connor, T., and Gallinac, A.M. 1983. Cholangiocarcinoma in a Yellow-Faced Amazon Parrot (*Amazona xanthops*). *Avian Diseases*, **27**: 2, 556-558.
- Rigdon, R.H. 1972. Tumors in the ducks (Family anatidae): a review. *J. Nat. Can. Inst.* **49**, 467- 476.
- Zachary, J.F. and Mcgavin, M.D. 2012. Pathologic basis of veterinary disease. 5th edn., Elsevier Mosby, Missouri, 1322 p.

**Prasad C¹, Ajith Jacob George²,
Mammen.J.Abraham³, S.S. Devi⁴,
B. Dhanushkrishna⁵, C. Divya⁶**
Department of Veterinary Pathology,
College of Veterinary and Animal Sciences,
Mannuthy, Thrissur, Kerala, India – 680651.

1. *M.V.Sc Scholar*

2. *Professor and Head, Dept of Veterinary Pathology, Pookode, Wayanad*

3. *Professor & Head*

4,5,6. *Assistant Professors*