



## THERAPEUTIC MANAGEMENT OF BLOOD FLUKE INFECTION IN AN INDIAN ELEPHANT – A CASE REPORT

Received : 03.07.2016

Accepted : 06.07.2016

*Bivitellobilharzia nairi* is a poorly understood trematode belonging to the family Schistosomatidae that has a profound impact on its host species, the elephant. The pernicious effects of the different life stages of this parasite can often be fatal. The first reports of schistosomosis in African and Asian elephants were published by Vogel and Minning (1940) and Mudaliar and Ramanujachari (1945), respectively. The morphologies of ova and adult helminths of *B.nairi*, the schistosome affecting Indian elephants (*Elephas maximus indicus*) have been described in detail by Rao and Hiregaudar (1935), Sundaram *et al.* (1972), Chandrasekharan (1989), Islam (1994) and Vimalraj *et al.* (2012). According to Bhojar *et al.* (2014), the infection remains subclinical in most cases and is only discovered upon post-mortem examination. More recently, Devkota(2015) found that *Bivitellobilharzia* spp. infects both, captive and wild Asian elephants. Karawita *et al.* (2015) claimed to report the first death of an Asian elephant due to caecocolic intussusception on account of schistosomosis.

A 22 year old captive Indian elephant was presented with a history of recurrent gastrointestinal disturbances. The faeces had a pasty consistency and emanated a foul smell. Faecal samples and blood from this elephant were collected for analysis. Upon direct microscopic examination of the faecal sample, no ova of parasitic importance were found, whereas examination after sedimentation of the sample at 2500 rpm for 10 minutes revealed the presence of ovoid eggs with a projecting spine and a well-developed miracidium within. The egg was identified as *B. nairi* (Fig. 1).

The haematological parameters of the elephant were estimated using automatic haematology analyser. Serum biochemistry analysis was carried out using a semi-automatic analyser and commercially available kits (Cormay Group). Hematobiochemical parameters of the elephant along with the reference ranges are listed in Table 1.

The haematobiochemical analysis revealed a mild reduction in leukocytes, lymphocytes and monocytes, and ALT (alanine amino transaminase) when compared to the normal range.

The elephant was administered a combination of fenbendazole and praziquantel (Fentas plus) @ 2.5 mg/kg orally, along with bread and jaggery, followed by a second dose, 4 weeks later. The elephant was also administered amoxicillin-sulbactam (Amoxirum forte) @ 7.5 mg/kg, intravenously for three days to prevent secondary bacterial infection

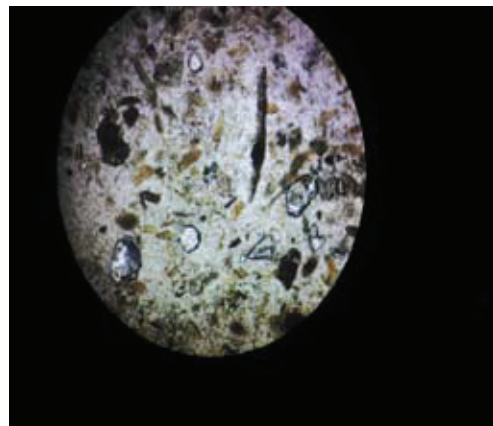


Fig. 1: Ovum of *Bivitellobilharzia nairi*

Table 1: Haematobiochemical parameters

Parameters	Result	Reference Range	Parameters	Result	Reference Range
WBC (10 <sup>3</sup> /μl)	9.6	10–18	Total protein (g/dl)	9.2	6-14
Lymphocytes (10 <sup>3</sup> /μl)	3	5-8	Albumin (g/dl)	3.08	1.5-4
Monocytes 10 <sup>3</sup> /μl	1.8	2-4	Globulin (g/dl)	6.12	2.5-10.7
Granulocytes (10 <sup>3</sup> /μl)	4.8	2-5	A:G ratio	0.503	0.43-0.92
RBC (10 <sup>6</sup> /μl)	4.12	2.5-5	ALT (IU)	1.785	7-11
Hb (g/dl)	11.4	11-15	ALP (IU)	174.6	91-289
VPRC (%)	35	30-40	BUN (IU)	14.48	3-28
Platelets (10 <sup>3</sup> /μl)	318	200-600	Creatinine (mg/dl)	1.278	1-3.8
			AST (IU)	26.48	5.5-27.2

and 70 ml of Artizone S (phenyl butazone and sodium salicylate combination), intravenously. The elephant recovered uneventfully, and the faecal sample was found negative for any ova of parasitic importance when examined two months later.

The protocol followed for administration of fenbendazole-praziquantel combination proved to be successful in this case as reported by Bhojar *et al.* (2014). The comprehensive understanding of a parasite is of utmost importance since it aids in adopting effective treatment protocols and control measures to restrict its prevalence at harmless levels. A thorough understanding of the biology of *B. nairi* is essential in order to augment the knowledge of parasite fauna of wildlife as well as mitigate the disastrous consequences of the parasite on the well-being of the host.

## SUMMARY

A 22 year old elephant with a history of anorexia, recurrent gastrointestinal disturbances and pasty consistency of the dung was diagnosed with blood fluke infection based on the presence of *B. nairi* ova in the faecal sample. The animal was successfully treated with a combination of fenbendazole and praziquantel.

## References

Bhojar, R., Pradeep, B. S., Kulkarni, S., Kasaralikal, V. R. and Patil, N. A. 2014.

Schistosomiasis in Asian Elephants. *Gajah*. **40**: 35-38.

Chandrasekharan, K. In: The Asian Elephant: Ecology, Biology, Diseases, Conservation and Management. *Proceedings of the National Symposium on the Asian Elephant*; 16<sup>th</sup> to 19<sup>th</sup> January, 1989, Thrissur. Kerala Agricultural University, Thrissur, India. pp. 148-155.

Devkota. 2015. Schistosomes of Nepal. *Ph.D. dissertation*, The University of New Mexico, Albuquerque, New Mexico, 155p.

Islam, S. 1994. Occurrence of *Bivitellobilharzia nairi* in captive Assam elephants in (*Elephas maximus*) from Kaziranga National Park and Assam State Zoo, Guwahati. *Zoos' Print J.* **9**: 10-11.

Karawita, A. C., Rajapakse, R. C., Amarasiri, P. G. I. D., Ramanayake, R. M. T. M., Jayaweera, W. R., Bollinger, T. K. and Gunawardena, G. S. P. De. S. 2015. Cecocolic intussusception in an Asian elephant (*Elephas maximus*) in Sri Lanka associated with chronic hepatointestinal schistosomiasis: first case report. *Int. J. Appl. Sci. Biotechnol.* **3**: 744-746.

Mudaliar, G. and Ramanujachari, G. 1945. *Schistosoma nairi* n.sp from an elephant. *Indian Vet. J.* **22**: 1-4.

Rao, S. R. and Hiregaudar, L. S. 1954. Schistosomiasis in elephants in Bombay state. *Indian Vet. J.* **30**: 241-241.

Sundaram, R.K., Iyer, R.P., Peter, C.T. and Alwar, V. S. 1972. On *Bivitellobilharzia nairi* (Mudaliar

and Ramanujachari, 1945) Dutt and Srivastava, 1955 (Trematoda: Schistosomatidae) parasitic in Indian elephants (*Elephas maximus*), with a redescription of the species. *Indian Vet. J.* **49**: 1-10.

Vimalraj, P.G., Jayathangaraj, M.G., Sridhar, R., Senthilkumar, T. M. A. and Latchumikanthan, A.

2012. Elephant schistosome (*Bivitellobilharzia nairi*) in free-ranging Asian elephants (*Elephas maximus*) of Sathyamangalam forest division of Tamil Nadu State. *J. Vet. Parasitol.* **26**: 80-88.

Vogel, H. and Minning, W. 1940 Bilharziose bei Elefanten. *Archiv für Schiffs und Tropenhygiene.* **44**: 562-574. ■

**V. R. Amulya<sup>1</sup>, P. V. Tresamol<sup>2</sup>,  
K. Vinodkumar<sup>3</sup>, Bindu Lakshmanan<sup>4</sup>,  
T. S. Rajeev<sup>5</sup> and S. Sulficar<sup>3</sup>**

*Department of Veterinary Epidemiology and  
Preventive Medicine  
College of Veterinary and Animal Sciences,  
Mannuthy, Thrissur -680651.*

1. MVSc Scholar
2. Professor and Head
3. Assistant Professor
4. Assistant Professor, Department of Veterinary, Parasitology
5. Assistant Professor, Department of Veterinary and Animal Husbandry Extension