



# CLINICOBIOCHEMICAL AND HISTOPATHOLOGICAL STUDIES OF FIBROADENOMA WITH PARAPROSTATIC PSEUDOCYST AND INFLAMMATION IN A GERMAN SHEPHERD DOG\*

Received - 08.10.10

Accepted - 05.04.11

Paraprostatic cyst is one of the rarest prostatic diseases in dogs (Krawiec, 1994). Data from the literature regarding fibroadenoma with paraprostatic pseudocyst is scarce. The most common cyst biopsied and submitted was the paraprostatic pseudocyst (Hoffer, 1977). The term pseudocyst is used since the inner lining is seldom lined by epithelium and therefore impossible to determine its origin. Krawiec and Heflin (1992) reported that paraprostatic cyst is usually seen in middle and old aged dogs. The present note communicates a case of fibroadenoma with paraprostatic pseudocyst and subsequent inflammation in a dog.

A German shepherd male intact dog aged three and a half years presented to the Veterinary College Hospital, Mannuthy, with the history of pyrexia, anorexia, intermittent urination, haematuria and dyschezia for 10 days was utilised for the present study. The animal was subjected to detailed clinical examination, transrectal digital palpation of prostate, ultrasonography and prostatic fluid cytology. Blood sample collected on the day of admission was used for analysis of haemoglobin, volume of packed red cells (VPRC), erythrocyte sedimentation rate (ESR), total erythrocyte count (TEC), total leucocyte count (TLC) and differential leucocyte count (DLC). Total protein, albumin, globulin, albumin globulin ratio, creatinine, blood urea nitrogen (BUN), calcium, glucose, testosterone, total acid phosphatase and prostatic acid phosphatase were estimated using standard procedure.

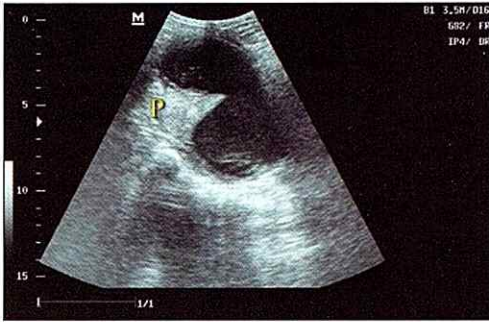
Clinical signs observed in the present study agree with the observations made by

Davidson (2003). Purulent urethral discharge and elevated temperature in the present case might be due to secondary infection of the prostate which developed due to prevention of urine flow during micturition by the paraprostatic cyst as reported by Dorfman and Barsanti (1995). Ultrasonography revealed two anechoic cavities containing mixed echogenic substances with irregular thickened borders dorsolateral to the prostate, which was diagnosed as paraprostatic cyst on necropsy (Fig.1).

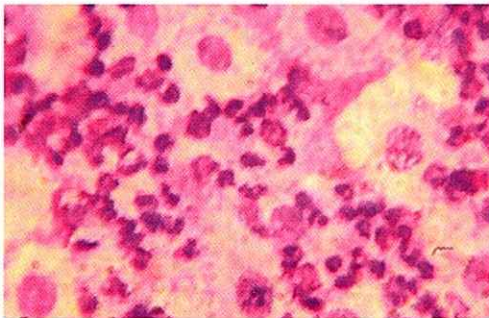
Prostatic fluid aspirated was serosanguinous to brown coloured and cytological evaluation revealed distorted, damaged cells resembling neutrophils and prostatic cells with anisocytosis (Fig. 2). *Pseudomonas* organism was identified on cultural examination of prostatic fluid. The same pathogen could be cultured from urine also. Hence, it could not be established that the pathogen isolated from prostatic fluid originated from the prostate gland.

Clinico pathological studies revealed mild anaemia with severe leucocytosis and neutropenia as reported earlier by Davidson (2003). The severe neutropenia might be due to initial stage of an acute bacterial infection or due to reduced mature granulocyte survival because of excessive destruction or utilisation which is seen in overwhelming bacterial infection and hypersplenism. The above changes could be correlated with ultrasonographic findings and autopsy. Hypoalbuminaemia with hyperglobulinaemia (1.9 g/dl and 5.3 g/dl), azotaemia (5.4 mg/dl), hypocalcaemia (7 mg/dl) and hypoglycaemia (50 mg/dl) could be observed in the present study. Davidson (2003) reported increased

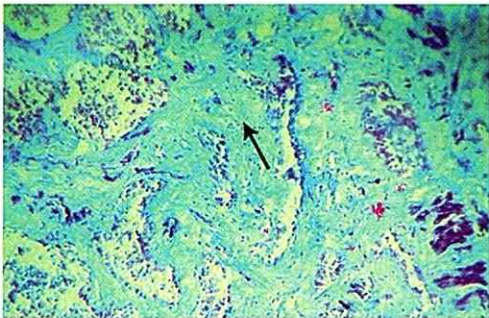




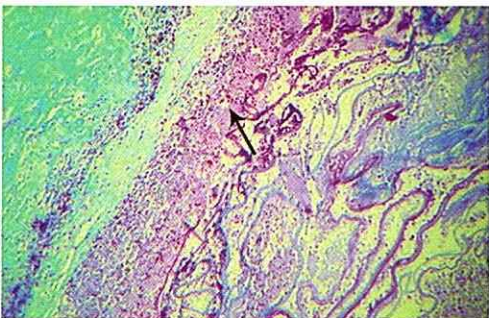
**Fig.1.** Anechoic cavities containing mixed echogenic substances



**Fig.2.** Prostatic cells with anisocytosis



**Fig.3.** Fibrous tissue proliferation



**Fig.4.** Infiltration of lymphocytes and plasma cells

alkaline phosphatase, varying levels of serum calcium, hypoalbuminaemia and azotaemia in prostatic neoplasia. Hyperglobulinaemia might be due to acute inflammatory process.

Normal level of serum total acid phosphatase (1 U/L) with prostatic fraction (0.4 U/L) was found in the present study. The low serum concentrations of total acid phosphatase and prostatic acid phosphatase did not rule out prostatic adenocarcinoma in the dog, but elevated concentrations in prostatic adenocarcinoma compared to benign prostatic hyperplasia (BPH) could be the useful criteria for differentiating the tumor from BPH (Corazza *et al.*, 1994). Normal serum testosterone level was observed.

Eventhough the animal was treated based on culture and sensitivity test the animal did not respond to the treatment adopted due to advanced renal failure. Treatment of canine prostate cancer was generally unrewarding. Surgical resection usually is not usually recommended, because the disease was not usually diagnosed at an early stage, and prostatic surgery often resulted in urinary incontinence (Johnston *et al.*, 2000).

Histopathology of prostate revealed adenomatous and fibrous tissue proliferation and diffuse infiltration of lymphocytes and plasma cells. Since the inner wall was devoid of continuous epithelium, its origin could not be found out and hence the cyst was termed as pseudocyst (Hoffer *et al.*, 1977). The presence of fibrous tissue proliferation was confirmed by Gomori's trichrome one step method (Fig.3). Both the prostate and paraprostatic cyst had infiltration of lymphocytes and plasma cells (Fig.4) indicating concurrent chronic inflammation as opined by Kustritz and Klausner (2000).

## Summary

Paraprostatic cyst is one of the rarest prostatic diseases in dogs. The present case was a fibroadenoma with paraprostatic pseudocyst diagnosed in a German shepherd male intact dog aged three and a half years which had the history of pyrexia, anorexia, intermittent urination, haematuria and dyschezia. Detailed clinical examination, ultrasonography, per rectal digital palpation of prostate, prostatic fluid cytology and clinico biochemical parameters were studied. The case was confirmed as fibroadenoma with paraprostatic pseudocyst after histopathological studies with Gomori's one step trichrome method.

## Acknowledgement

The authors are thankful to the Dean, College of Veterinary and Animal Sciences, Mannuthy for providing necessary facilities to carry out this research work.

## References

- Corazza, M., Guidi, G., Romagnoli, S., Tognetti, R. and Buonaccorsi, A. 1994. Serum total prostatic and non-prostatic acid phosphatase in healthy dogs and in dogs with prostatic diseases. *J. Small. Anim. Pract.*, **35**: 307-310.
- Davidson, J. R. 2003. Prostatic diseases of the dog. *Waltham Focus*, **13**:4-10.
- Dorfman, M. and Barsanti, J. A. 1995. Treatment of canine bacterial prostatitis. In : Bonagura J.D. and Kirk, R.W. (Eds.). *Current Veterinary Therapy XII*. WB Saunders, Philadelphia, pp. 1029-1032.
- Hoffer, R. E., Dykes, N. L. and Greiner, T. P. 1977. Marsupialization as a treatment for prostatic disease. *J. Am. Anim. Hosp. Assoc.*, **13**:98-104.
- Johnston, S. D., Kamolpatana, K., Kustritz, M. V. R. and Johnston, G. R. 2000. Prostatic disorders in the dog. *Ani. Reprod. Sci.*, **60**:405- 415.
- Krawiec, D. R. and Heflin, D. 1992. Study of prostatic diseases in dogs: 177 cases (1981-1986). *J. Am. Vet. Med. Assoc.*, **200**:1119.
- Kustritz, M. V. R. and Klausner, J. S. 2000. Prostatic diseases. In: Ettinger, S. J. and Feldman (Eds.) *Textbook of Veterinary Internal Medicine Diseases of Dog and Cat*. 5<sup>th</sup> ed. W. B. Saunders Company, Philadelphia, pp. 1687-1698.

Sindhu K. Rajan<sup>1</sup>, Usha Narayana Pillai<sup>2</sup>,  
P. C. Alex<sup>3</sup>, K. M. Jayakumar<sup>4</sup>, Metilda Joseph<sup>5</sup>,  
Syam K. Venugopal<sup>6</sup>

Department of Clinical Veterinary Medicine  
College of Veterinary and Animal Sciences  
Mannuthy - 680 651, Thrissur, Kerala

\* Part of M.V.Sc. thesis submitted by the first author to the Kerala Agricultural University, Thrissur

<sup>1</sup> Veterinary Surgeon, AHD, Kerala

<sup>2</sup> Associate Professor

<sup>3</sup> Director of Clinics, KVASU

<sup>4</sup> Professor and Head, University Veterinary Hospital, Kollalai

<sup>5</sup> Associate Professor, Dept. of Gynaecology, Obstetrics and Animal Reproduction

<sup>6</sup> Associate Professor, Dept. of Veterinary Surgery and Radiology