



A COMPARATIVE STUDY ON THE PECTORAL GIRDLE OF GREEN-WINGED MACAW AND PEAHEN*

V. R. Indu¹, K. M. Lucy², A. R. Sreeranjini³,
S. Maya⁴, N. Ashok⁵ and K.V. Syam⁶

Department of Veterinary Anatomy and Histology
College of Veterinary and Animal Sciences
Mannuthy 680 651, Thrissur, Kerala

Received - 07.12.2011
Accepted - 14.05.2012

Abstract

A study was conducted on the pectoral girdle of eight year old male green-winged macaw and adult peahen to compare the gross features of the bones and to correlate their morphological peculiarities with its possible functions. The skeleton of the pectoral girdle consisted of clavicle, coracoid and scapula in both the species but presented striking deviations. In peahen, the scapula presented a flat coracoid process, coracoid had a hook-like furcular tuberosity and furcula was V-shaped with a prominent hypocleidium. In green-winged macaw the scapula had a truncated caudal extremity with a convex coracoid process whereas, the coracoid showed a tuberosus furcular tuberosity and a well developed scapular process. The furcula was U-shaped with a prominent caudal process, while the hypocleidium was absent. All the bones were comparatively stronger in green-winged macaw which could be an adaptation towards the functions necessary to perform the flight stroke.

Keywords: Green-winged macaw, Peahen, Pectoral girdle

The wings are the key to birds' flight. The pectoral girdle forms the connection

between the trunk and wings. The present study was undertaken to compare the gross features of the bones of pectoral girdle in green-winged macaw and peahen and to correlate their morphological peculiarities with its possible functions.

Materials and Methods

The pectoral girdle of eight year old male green-winged macaw and adult peahen were collected. After natural maceration the bones were cleaned and observed for gross anatomical features.

Results and Discussion

The skeleton of the pectoral girdle consisted of fused clavicles (furcula), coracoid and scapula. The scapula of both green-winged macaw and peahen were sword-like but in macaw it was a short and stout bone. It was positioned lateral and parallel to the vertebral column and extended caudally to the pelvis as in fowl (Dyce *et al.*, 2002). The scapula presented two surfaces viz., a convex costal surface and a concave dorsolateral surface. The dorsal border was thin and convex in peahen but in green-winged macaw it presented a sharp downward bend posteriorly. The ventral border was rounded and concave.

1 & 3 Assistant Professors

2 & 4 Associate Professors

5. Professor and Head

6. Associate Professor and Head, Dept. of Veterinary Surgery & Radiology

The cranial or articular extremity of scapula presented a pointed acromion or clavicular process medially, which formed a syndesmotomic union with clavicle in both the species. The coracoid process was seen on the medial aspect for the coracoid and was flat in green-winged macaw whereas in peahen it was a convex protuberance as in fowl (Nickel *et al.*, 1986). This difference in shape of coracoid process might be due to the contact with the well-developed scapular process in the coracoid of Green-winged macaw which was absent in peahen. On the lateral aspect of cranial extremity a concave articular surface was seen for the head of humerus (Fig.1).

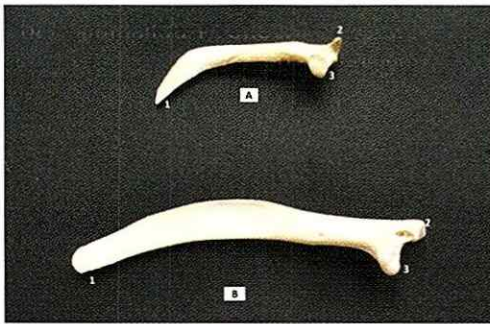


Fig.1. Scapula of green-winged macaw (A) and peahen (B) - Medial aspect.

1. Caudal extremity 2. Acromion process 3. Coracoid process

The coracoid was the strongest bone of pectoral girdle in both the species. It articulated with the sternum at the sternocoracoid articulation and with the scapula, clavicle and humerus at the shoulder joint. The major part of the glenoid fossa for head of humerus was contributed by coracoid while the scapula only contributed a small part of the fossa (Ruijin *et al.*, 2000). The shaft of the bone was oval in the center but at its extremities it was compressed in the antero-posterior direction and faintly marked by muscular lines. The proximal extremity presented a tuberosity furcular tuberosity, which was inclined slightly forwards and towards the median line for articulation with the clavicle in green-winged macaw. Below it was the glenoid fossa and a well developed scapular process to provide for extensive ligamentous attachment; but in peahen the furcular tuberosity was hook-shaped and scapular process was absent as in domestic fowl (Nickel *et al.*, 1986). These variations might

be the adaptations to counteract the powerful forces exerted by the pectoral muscles during flight in green-winged macaw. The stronger coracoids helped to hold the wings away from sternum during flight while the ribs prevented the thorax from collapsing during the downward stroke of the wings (King and Mc Lelland, 1975). The distal or sternal extremity presented a wide sternal articular surface which was concave transversely and convex vertically to eliminate all movement except extension and flexion. In both the species, the sternal extremity presented a well marked lateral process at the exterio-inferior angle (Fig.2).

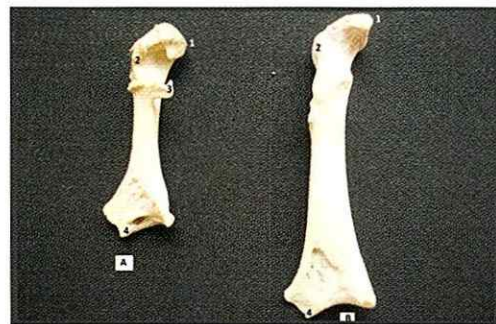

Fig.2. Coracoid of green-winged macaw (A) and peahen (B) - Medial aspect.

1. Furcular tuberosity 2. Glenoid cavity 3. Scapular process 4. Lateral process

In peahen, the right and left clavicles fused ventrally at an acute angle to form V-shaped furcula while in green-winged macaw, it was U-shaped. This might be because the shape of the furcula was functionally related to general differences in flight requirements. Hui (2002) reported that in soaring birds the furculae were more U-shaped or circular than those of flapping birds. At the clavicular junction

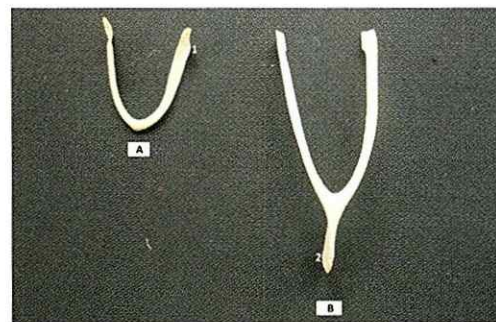


Fig.3. Furcula of green-winged macaw (A) and peahen (B) - Cranial aspect.

1. Caudal process for coracoids 2. Hypocleidium

a sagittal bony plate called hypocleidium was present in the peahen but absent in green-winged macaw (Fig. 3). According to Mc Lelland (1990), in parrots furcula was incomplete and the union at their medio-inferior points was very feeble. In green-winged macaw, the proximal end of the two branches of furcula was broad and carried a caudal process which served for the syndesmotric union with the furcular tuberosity of the coracoid while its pointed ends attached to the acromion process of scapula by a ligament similar to that seen in ducks (Nickel *et al.*, 1986). In peahen, the branches were thin and slightly curved caudally but the caudal process was absent. Acting like springs, the furcula maintained the distance between shoulder joints during wing movement (Nickel *et al.*, 1986). In both the species, the clavicle, coracoid and scapula met together dorsally leaving a foramen triosseum. Getty (1975) reported that this foramen served for the passage of the tendon of supracoracoideus muscle which inserted on the dorsal aspect of humerus, to elevate the wing, thereby forming an important part of the flight mechanism.

References

- Dyce, K.M., Sack, W.O. and Wensing, C.J.G. 2002. *Textbook of Veterinary Anatomy*. 3rd ed., W. B. Saunders Company, Philadelphia. 840p.
- Getty, R. 1975. *Sisson and Grossman's the Anatomy of the Domestic Animals*. Vol II, 5th ed., W. B. Saunders Company, Philadelphia. 2095p.
- Hui, C. A. 2002. Avian furcula morphology may indicate relationships of flight requirements among birds. *J. Morphol.*, **251**:284-293
- King, A.S. and Mc Lelland, J. 1975. *Outlines of Avian Anatomy*. Bailliere Tindall, London. 152p.
- Mc Lelland, J. 1990. *A Colour Atlas of Avian Anatomy*. Wolfe Publishing Ltd., England. 127p.
- Nickel, R., Schummer, A. and Seiferle, E. 1986. *Anatomy of the Domestic Birds*. Verlag Paul Parey, Berlin, Hamburg. 202p.
- Ruijin, H., Qixia, Z., Ketan, P., Jörg W., and Bodo C. 2000. Dual origin and segmental organisation of the avian scapula. *Development*, **127**: 3789-3794
- Dyce, K.M., Sack, W.O. and Wensing, C.J.G. 2002. *Textbook of Veterinary Anatomy*. □