



# SUITABILITY OF TICK TISSUE STAINING FOR THE DIAGNOSIS OF BABESIOSIS IN CATTLE\*

T. S. Rejitha<sup>1</sup> and K. Devada<sup>2</sup>

Department of Veterinary Parasitology  
College of Veterinary and Animal Sciences  
Mannuthy-680 651, Thrissur, Kerala

## Abstract

In the present study, an attempt was made to identify the cattle with clinical or subclinical babesiosis by demonstrating the developmental stages of *Babesia bigemina* in the tissues of ticks collected from suspected animals. Ticks collected from 50 cattle presented at various Veterinary Hospitals of Thrissur and Ernakulam districts of Kerala and those belonging to University Livestock Farm, Mannuthy and Cattle Breeding Farm, Thumburmuzhi were subjected to study. Salivary glands, gut and ovaries were separated from the ticks and stained with methyl green pyronine. Considering the ticks as positive on detection of developmental stages of the parasite in any of the three tissues, ticks from 27 (54 per cent) out of total 50 animals were interpreted as positive. Examination of tick tissues was found as effective for detecting the clinical and subclinical forms of babesiosis in cattle and found as a suitable epidemiological tool.

**Key words:** *Babesia bigemina*, *Boophilus annulatus*, Methyl green pyronine

The identification of organisms in thin and thick blood films is a true evidence of infection, however a negative result does not rule out the possibility of infection. Besides, animals which recover from an acute infection become carriers of the haemo-parasite in course of time making diagnosis difficult. The detection of parasitic stages in the vector becomes essential, as this forms a component

for assessing the infection rate in vectors and also helps to curtail the risk of babesiosis in enzootic areas. Sundar *et al.* (1993) used methyl green pyronine to stain salivary glands of *Hyalomma anatolicum anatolicum* and detected the developmental stages of *Theileria annulata* in the acini. This paper reports the diagnosis of babesiosis in cattle by tick tissue examination.

## Materials and Methods

### Collection of ticks

Partially engorged ticks were collected manually from the body of animals suspected for babesiosis. These animals were those that were either presented at the Veterinary Hospitals or maintained at the Livestock Farms of the KAU. The ticks were carried to the laboratory in clean glass vials covered with a piece of muslin cloth and identified before dissection. About two hundred ticks were collected from a total of 50 animals. Blood smears from these animals were also examined with Giemsa's stain.

### Dissection and staining

Dissection of ticks and staining of tick tissues was done as per the method devised by *Irvin et al.* (1981) with a few modifications.

The cleaned ticks were held in between the thumb and forefinger with the dorsal side up and dissected with a sharp blade from the posterior boarder proceeding anteriorly to expose the viscera. Dissected ticks in phosphate buffered saline were examined

\* Part of M.V.Sc. thesis submitted by the first author to the Kerala Agricultural University, Thrissur

1. Veterinary Surgeon, AHD, Kerala

2. Professor & Head

under a dissecting microscope (10 x 15X). Paired salivary glands visible anteriorly on either side of trachea were removed carefully with a teasing needle and transferred with a drop of the medium to microscopic slides for further examination. Gut that appeared as brownish strands in the central area and the ovaries visible as a bunch of grapes towards the posterior part were separated and spread on different glass slides in PBS. Care was taken to complete the teasing and separation of tick tissues, before the preparations dried up.

The preparations on the slides were then air dried and fixed for two to five minutes in Carnoy's fixative. They were then rinsed for two min in 70 per cent alcohol, followed by a rinse in distilled water for another two minutes. Then the slides were immersed in two percent methyl green pyronine for seven to nine minutes. After staining, the slides were rinsed in distilled water, air dried and mounted in DPX mountant.

Slides were scanned at 100X and 400X of a light microscope to detect the developmental stages of *Babesia*, if any.

## Results and Discussion

Ticks recovered from the cattle were identified as *Boophilus annulatus*. Rajamohanam (1980) opined that *B. annulatus* was the most important vector of babesiosis in Kerala.

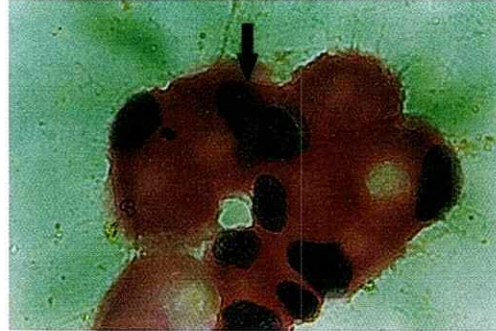Since the literature on methyl green pyronine staining of salivary glands, gut and ovaries of *Boophilus sp.* was scarce, reports pertaining to *Theileria sp.* in other Ixodid ticks were referred to in this study.

Distribution of parasitic stages in different tissues had a tendency to vary. Hence it was necessary to examine the salivary glands, gut and ovaries before interpreting the conclusive results.

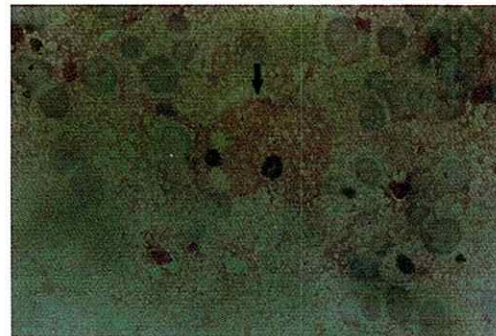
A tick was interpreted as positive if any one of the three tissues revealed parasitic stages. Accordingly, 27 (54 per cent) out of 50 animals with tick infestation were designated as positive for *Babesia* organisms. In the present study, none of the ticks maintained the parasitic stages in the ovaries alone.

Infected salivary gland acini appeared hypertrophied with pink acinar cell cytoplasm and the blue nucleus. Deep blue coloured mass indicative of the parasite was also

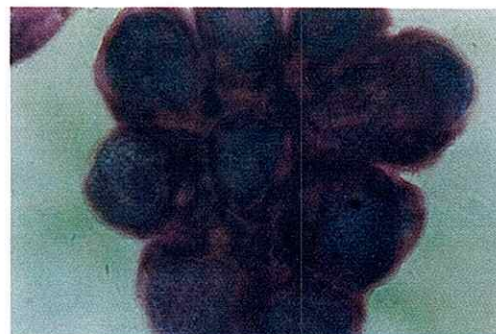
detected (Fig. 1). In the gut, the presence of parasitic stages was indicated by the hypertrophy of infected epithelial cells and vacuolations in the cell cytoplasm (Fig. 2). The oocytes in the ovaries also revealed blue coloured spherical masses denoting the developmental stages of the parasite (Fig. 3).



**Fig. 1** - Infected tick salivary gland: Hypertrophied acini with parasitic mass



**Fig. 2**. Infected tick gut-cells: Hypertrophy and vacuolation of cytoplasm



**Fig. 3**. Infected tick ovary: Infected oocytes with parasitic mass

Five animals out of 50, which were positive for babesiosis by tick examination, were also positive for the organisms in the blood smear. Meanwhile, 22 animals were negative for the organisms in blood smear as well as in the ticks collected from them. Another

22 of the total animals which rendered negative results by blood smear examination, were actually detected as positive upon tick examination. There was only one animal from which infected ticks were not recovered, that rendered a positive smear.

All the animals that exhibited acute symptoms of the disease were found positive for the parasitic stages in ticks where as only 20 animals with a sub clinical infection carried infected ticks.

This study agrees with *Walker et al.* (1983) who found tick collection and staining methods as suitable for the infections of *H. anatolicum* with *Theileria annulata*. As dissection of ticks and identification of parasitic stages is fraught with difficulties, this method may be combined with other diagnostic tests for eventually coming to a conclusion. However, examination of ticks in studies related to the epidemiology of babesiosis, looks promising, as subclinical infections could be detected by this method.

## References

- Gautam, O.P. and Chhabra, M.B. 1983. Babesiosis – Recent advances with special reference to India. *Trop. Vet. Anim. Sci. Res.*, 1: 201-207.
- Irvin, A.D., Boarer, C.D.H., Dobbelaere, D.A.E., Mahen, S.M., Masake, R. and Ocana, J.G.R. 1981. Monitoring *Theileria parva* infection in adult *Rhipicephalus appendi-culatus* ticks. *Parasitology*, 82: 137-147
- Rajamohanan, K. 1980. Studies on the common ticks in livestock in Kerala. *Ph.D. thesis*. Kerala Agricultural University, Thrissur. 218p
- Sundar, N., Balasundram, S. and Anandan, R. 1993. Intensity of *Theileria annulata* infections with salivary glands of *Hyalomma anatolicum anatolicum*. *Cheiron*, 22:2-4
- Walker, A.R., Latif, A.A., Morzaria, S and Jongejan. F. 1983. Natural infection rates of *Hyalomma anatolicum anatolicum* with *Theileria* in Sudan. 35:87-90

