



# Fresh preserved canine amniotic membrane (CAM) as graft for surgical management of melting corneal ulcer/ keratomalacia in a dog

Anju Mary John<sup>1</sup>, N. S. Jinesh Kumar<sup>2</sup>, S. Sooryadas<sup>2</sup>,  
P. T. Dinesh<sup>2</sup>, K. P. Surjith<sup>2</sup>, V. Remya<sup>2</sup> and S. Anoop<sup>3</sup>

Department of Veterinary Surgery and Radiology  
College of Veterinary and Animal Sciences,  
Pookode, Wayanad, Kerala- 673 576

Citation: Mary John,A., Jineshkumar,N.S., Sooryadas,S., Dinesh,P.T., Surjith,K.P. Remya,V. and Anoop,S. 2023. Fresh preserved canine amniotic membrane (CAM) as graft for surgical management of melting corneal ulcer/ keratomalacia in a dog. *J. Vet. Anim. Sci.* 54(1):266-268

DOI: <https://doi.org/10.51966/jvas.2023.54.1.266-268>

Received: 10.10.2022

Accepted: 28.11.2022

Published: 31.03.2023

## Abstract

A four-year-old female Spitz with signs of blepharospasm, ocular discolouration, corneal oedema, gelatinisation of cornea and epiphora from the right eye, for 20 days was presented at Teaching Veterinary Clinical Complex, Pookode. Fluorescein dye test (FDT) revealed intense staining of the cornea. The condition was diagnosed as keratomalacia. Under general anaesthesia, fresh preserved canine amniotic membrane (CAM) transplantation was performed along with a third eyelid flap. Antibiotic eye drops and supportives were initiated. Monitoring of corneal healing was done on the 10<sup>th</sup>, 20<sup>th</sup>, 30<sup>th</sup> and 45<sup>th</sup> days, post-surgery. FDT turned negative on day 20. Conjunctival hyperaemia, pannus, corneal opacity and oedema improved postoperatively, resulting in good corneal clarity, fundic reflection and normal vision by day 45. The present article reports the successful management of keratomalacia using CAM as graft.

**Keywords:** Canine amniotic membrane, keratomalacia, corneal ulcer

Corneal ulcer is one of the most common ocular disorders in dogs and cats. Tsvetanova *et al.* (2021) mentioned keratomalacia/ melting corneal ulcer as a complication of an already existing corneal ulcer. Keratomalacia is an ophthalmic emergency and if left untreated, can ultimately lead to endophthalmitis and vision loss. Therefore, appropriate treatment of keratomalacia is warranted. A myriad of biological membranes are available for use as graft material like human amniotic membrane, collagen grafts, porcine urinary bladder acellular matrix etc. Barros *et al.* (2005) had reported the use of CAM for treatment of keratomalacia in a dog for the first time, with favorable results. The anti-angiogenic, anti-inflammatory, anti-protease, epitheliotropic and anti-scarring

1. MVSc Scholar
2. Assistant professor
3. Professor and Head

\*Corresponding author: [jinesh@kvasu.ac.in](mailto:jinesh@kvasu.ac.in), Ph: 9447958763

Copyright: © 2023 John *et al.* This is an open access article distributed under the terms of the Creative Commons Attribution 4.0 International License (<http://creativecommons.org/licenses/by/4.0/>), which permits unrestricted use, distribution, and reproduction in any medium, provided the original author and source are credited.

properties of CAM, make it a versatile graft material for corneal reconstruction. Amniotic membrane forms the innermost layer of the fetal sac and consists of three layers namely stromal matrix, basement membrane and epithelial layer. The epithelium is adjacent to the fetus while the stromal matrix faces the chorion.

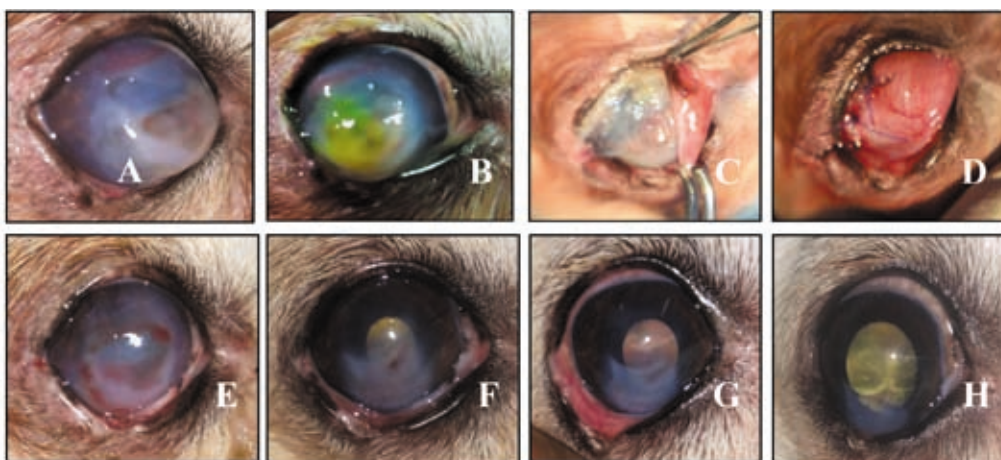
Amniotic membrane was aseptically harvested from a healthy Labrador Retriever during elective caesarean section. The harvested allanto-amnion thus collected was cleaned with sterile saline solution containing 0.1 mg/ml gentamicin and 2.5 mcg/ml amphotericin B as described by Kalpravidh *et al.* (2009). The amnion was then peeled off from the allantois. It was then spread onto a nitrocellulose paper of 0.45 microns pore size, with its epithelial surface up, and was stored in 98% glycerol at room temperature as mentioned by Barros *et al.* (2005). In the present study, CAM was used within one month of storage.

A four-year-old intact female Spitz weighing 8.3 Kg and good body condition score, was presented with blepharospasm, ocular discolouration and discharge from the right eye for the past 20 days. The physiological parameters as well as complete blood count did not reveal any systemic infection. Pronounced conjunctival hyperemia and profuse serous discharge were noticed in the affected eye. Visual function tests of the affected eye confirmed loss of vision. The corneal surface

had lost its normal contour and was found melting with a yellowish gelatinous appearance. (Fig. 1A). Fluorescein dye stained the melting cornea (Fig.1B). Surgical management with fresh preserved CAM as graft was resorted to.

Under general anaesthesia, eyelashes were clipped. The eye and adnexal structures were flushed with dilute povidone iodine solution (0.5 %) followed by sterile isotonic saline (0.9 %). Compromised corneal tissue and debris were removed using dry sterile cotton buds. Three layers of the CAM, with its stromal side facing cornea were secured in place by suturing at 360° over bulbar conjunctiva (Kalpravidh *et al.*, 2009) using 8.0 vicryl (Fig.1C). The grafted cornea was protected by a third eyelid flap (Fig. 1D). An Elizabethan collar was used until healing to protect the eye from self-trauma. Postoperatively, meloxicam at 0.3 mg/kg body weight was administered orally for 3 days and amoxicillin at 20 mg/kg body weight for a week. Topical instillation of moxifloxacin was continued four times daily, until complete healing and 1% atropine eye drops once daily for 4 days. Follow up examinations were done on day 10, 20, 30 and 45. Third eyelid flap suture was removed during initial re-check on day 10 post-operatively.

Corneal melting was found resolved and granulation of central cornea was noticed on day 10 of observation (Fig. 1E). This could be attributed to the inhibition of collagenases



**Fig.1:** (A) Keratomalacia, (B) Fluorescein dye-stained cornea, (C) Canine amniotic membrane layered cornea, (D) Third eyelid flap, (E) Appearance of cornea on day 10, (F) Appearance of cornea on day 20, (G) Appearance of cornea on day 30, (H) Appearance of cornea on day 45

by CAM as reported by Barros *et al.* (2005). Corneal surface appeared confluent by day 20 of observation and there was no fluorescein dye staining from day 20, confirmative of complete re-epithelialisation of cornea. These findings could be attributed to the rapid restoration of corneal epithelium by grafted CAM as reported by Barros *et al.* (2005). Dua *et al.* (2004) stated that, placement of membrane with stromal side facing cornea facilitates the graft to act as a scaffold for cellular migration, epithelialisation and incorporation to the host tissue. The superficial neovascularisation regressed progressively with only a single branching vessel at 7 o' clock position on day 45 of observation (Fig. H). The regression of superficial vascularisation could be attributed to the anti-angiogenic properties of CAM (Abbaszadeh *et al.*, 2010). Marked corneal oedema was noticed on day 0 of observation which resolved after grafting and no signs of oedema were noticed from day 20 of observation (Fig.1 F). Vision was absent in the dog on day 0 of observation and it gradually improved to normal on day 30 due to attainment of better corneal transparency (Fig.1G). The gain in transparency of cornea could be attributed to anti-inflammatory, anti-angiogenic, epitheliotropic and anti-scarring properties of CAM (Kalpravidh *et al.*, 2009). The anti-inflammatory effect of CAM could be attributed to reduced infiltration of polymorphonuclear leucocytes, expression of interleukin-10, interleukin-1 receptor antagonist and control of keratinocyte apoptosis. CAM exerts anti-scarring effect due to its anti-inflammatory properties and control of superfluous remodelling by inhibition of excessive fibroblast activation to myofibroblast. Fresh preserved CAM successfully managed the melting corneal ulcer in the dog studied.

### Summary

Successful management of keratomalacia in a dog using fresh preserved CAM is reported.

### Acknowledgements

Authors are thankful to the Dean, CV&AS, Pookode and Department of Animal Reproduction, Gynaecology and Obstetrics, CV&AS, Mannuthy, for providing required facilities for the study.

### Conflict of interest

The authors have no conflicts of interest.

### References

- Abbaszadeh, M., Aldavood, S.J., Foroutan, A.R., Azizzadeh, M. and SelkGhaffari, M. 2010. Effects of sutureless amniotic membrane patching with 2-Octyl cyanoacrylate (Dermabond) on experimental corneal alkali burn in dogs. *Comp. Clin. Path.* **19**(4):357-362.
- Barros, P.S., Safatle, A.M., Godoy, C.A., Souza, M.S., Barros, L.F. and Brooks, D.E. 2005. Amniotic membrane transplantation for the reconstruction of the ocular surface in three cases. *Vet. Ophthalmol.* **8**(3):189-192.
- Dua, H.S., Gomes, J.A., King, A.J. and Maharajan, V.S. 2004. The amniotic membrane in ophthalmology. *Survey Ophthalmol.* **49**(1):51-77.
- Kalpravidh, M., Tuntivanich, P., Vongsakul, S. and Sirivaidyapong, S. 2009. Canine amniotic membrane transplantation for corneal reconstruction after the excision of dermoids in dogs. *Vet. Res. Commun.* **33**(8):1003-1012.
- Tsvetanova, A., Powell, R.M., Tsvetanov, K.A., Smith, K.M. and Gould, D.J. 2021. Melting corneal ulcers (keratomalacia) in dogs: A 5 year clinical and microbiological study (2014–2018). *Vet Ophthalmol.* **24**(3): 265-278. ■